



PATIENT

Trooper Scott

SPECIES

Canine

BREED

German Shepherd

SEX

Femal Spayed

AGE

12 years

WEIGHT

78.7lbs

INTERPRETED BY

Maggie Machen Lamy,
DVM, DACVIM
(Cardiology)

IMAGING PERFORMED BY

Alastair Westcott,
DVM

HOSPITAL NAME

Alastair Westcott,
DVM

REFERRING VET

Dr. Westcott

PRESENTING CLINICAL SIGNS

History: Reduced energy levels and appetite. Resting respiratory rate 42-46. Coughing after drinking only, daily has been like this for year. Dramatic exercise intolerance. Heart murmur noted. Has tachycardia, hypertension and atrial fibrillation.

-Radiographs: Possible mild perihilar interstitial edema and LAE noted.

-ECG: Significant arrhythmia with pulse deficits.

ECHOCARDIOGRAM FINDINGS

2D, m-mode, color flow and doppler imaging is available. Severe left ventricular dilation with diminished systolic function. Decreased LV wall thickness with increased sphericity. Severe left atrial enlargement. The mitral valve appears normal in form and function, with no obvious prolapse into the left atrial lumen. Moderate eccentric mitral regurgitation secondary to annular stretch. Decreased velocity. Mild tricuspid regurgitation. Moderate right atrial and ventricular dilation. TR velocity consistent with mild pulmonary hypertension. The aortic valve is normal in morphology and mobility. No subvalvular ridge present; normal LVOT velocity. Trace aortic insufficiency. Normal pulmonic valve with trace pulmonic insufficiency seen. No pericardial or pleural effusion noted. No obvious cardiac tumors. Irregular rate and rhythm throughout.

CARDIAC CHART

CANINE CARDIAC PARAMETERS	MR VMAX (m/s)	TR VMAX (m/s)	LA/AO (Boon method)	LA/AO (Heart Base; Swe)	FS (%)	EF (%)	EPSS (cm)
NORMAL PARAMETER	4.5-5.5	<2.7	1.3	<1.6	28-40	40-100	<0.6
PATIENT	4.5	3.0	NM	2.5	19	40	1.1
CANINE CARDIAC PARAMETERS	HR (BPM)	AV VMAX (m/s)	PV MAX (m/s)	BODY WEIGHT (kg)	LA 2D short axis Base view (cm)	LVIDd Avg; 2D and m-mode short axis (cm)	LVIDs Avg; 2D and m-mode short axis (cm)
NORMAL PARAMETER	50-100	0.7-1.7	0.7-1.6	BELOW	BELOW	BELOW	BELOW
PATIENT	NM	1.0	0.8	35.7	5.2	5.3	4.3
*Normal chamber parameters expressed as a mean value (SD)				3	1.27 (5.3)	2.46 (2.46)	1.36 (5.5)
BODY WEIGHT DEPENDENT PARAMETERS				5	1.40 (4.5)	2.74 (5.2)	1.60 (4.7)
<i>*Note: All measurements based upon multi-modal images and methods. An average value is reported.</i>				10	1.50 (3.8)	3.27 (3.5)	2.06 (3.1)
				15	1.83 (2.0)	3.71 (2.4)	2.43 (2.1)
				20	2.02 (1.9)	4.14 (2.2)	2.80 (2.0)
				25	2.18 (2.4)	4.48 (2.9)	3.10 (2.5)
				30	2.33 (3.3)	4.83 (3.9)	3.39 (3.4)
				35	2.48 (4.3)	5.17 (5.0)	3.69 (4.5)
				40	2.62 (5.2)	5.48 (6.1)	3.96 (5.4)
				50	2.88 (7.1)	6.07 (8.3)	4.46 (7.4)

INTERPRETATION OF THE FINDINGS & FURTHER RECOMMENDATIONS

Unfortunately, this patient has significant cardiomyopathy and systolic dysfunction. This is causing dilation and volume overload of both the left and right heart resulting in insufficiency of the mitral and tricuspid valves. The severity of dysfunction and pump failure is severe, and the patient is at high risk for decompensating into congestive failure. Patient will always be at risk for right and/or left-sided CHF, development of arrhythmias/syncope and/or sudden death going

INVOICE

27073

DATE

10/24/22



PATIENT Trooper Scott	forward. There is suspicion for atrial fibrillation on the attached ECG and a full ECG evaluation is advised as rate control may be warranted.
SPECIES Canine	Systolic failure can be primary in nature (DCM) or secondary to taurine deficiency, myocarditis, hypothyroidism, tachycardia-induced cardiomyopathy, or infiltrative disease such as lymphoma. While primary disease is certainly possible, consider testing for primary causes that may be treatable. A troponin (cTnI) level can be submitted to further investigate infiltrative/inflammatory contribution (myocarditis). Additionally, a taurine level may be helpful (screen for malabsorption issue), and a thorough diet history given the recent correlation with grain free/boutique brand/exotic ingredient diets. Finally, further systemic evaluation for underlying infiltrative contribution such as neoplasia is also reasonable (abdominal ultrasound, etc.).
BREED German Shepherd	
SEX Femal Spayed	Regardless of cause, prognosis is guarded to poor at this stage in the disease process, with an average survival time of <6 months. The only treatable cause of systolic failure is diet/taurine deficiency, which is uncommon on commercially formulated dog foods. If the diet is of concern, highly recommend immediate diet change and taurine supplement regardless of blood taurine results. Please see the FDA website for more information.
AGE 12 years	
WEIGHT 78.7lbs	Immediate institution of full cardiac supportive medications is recommended as below due to high risk for decompensation and reported clinical signs. This includes diuretic therapy. Cases of systolic failure are at high risk for malignant tachyarrhythmias (such as VT or rapid AF) and sudden death, and this should be expressed to the owner. Activity restriction is advised, and a baseline ECG recommended.
INTERPRETED BY Maggie Machen Lamy, DVM, DACVIM (Cardiology)	Elective anesthesia is not advised due to high risk for complications.
IMAGING PERFORMED BY Alastair Westcott, DVM	Omega fatty acid supplementation and mild salt restriction may be of some long-term benefit. Monitor for development of a cough, worsening labored breathing, abdominal distention, exercise intolerance or collapse episodes in the future. Monitoring of sleeping breathing rates at home is recommended to assess response to medications and recurrence of CHF in the future.
HOSPITAL NAME Alastair Westcott, DVM	PLAN: Baseline BP/ECG recommended. Initiate aldosterone antagonist Spironolactone 1-2mg/kg PO q12h. Institute furosemide 1-2mg/kg PO q12h. Institute Pimobendan 0.3mg/kg PO q12h. Institute taurine 1000mg PO q12h. Diet history/change as discussed.
REFERRING VET Dr. Westcott	Monitor a renal panel and blood pressure in 1-2 weeks to ensure tolerance. If BP >130mmHg, institute ACEI 0.5mg/kg PO q12h. Consider cTnI, taurine level, AUS as discussed above.
INVOICE 27073	A recheck echocardiogram is recommended in 4-6 months to screen for progression, sooner if clinical issues arise in the interim.
DATE 10/24/22	



PATIENT

Trooper Scott

SPECIES

Canine

BREED

German Shepherd

SEX

Femal Spayed

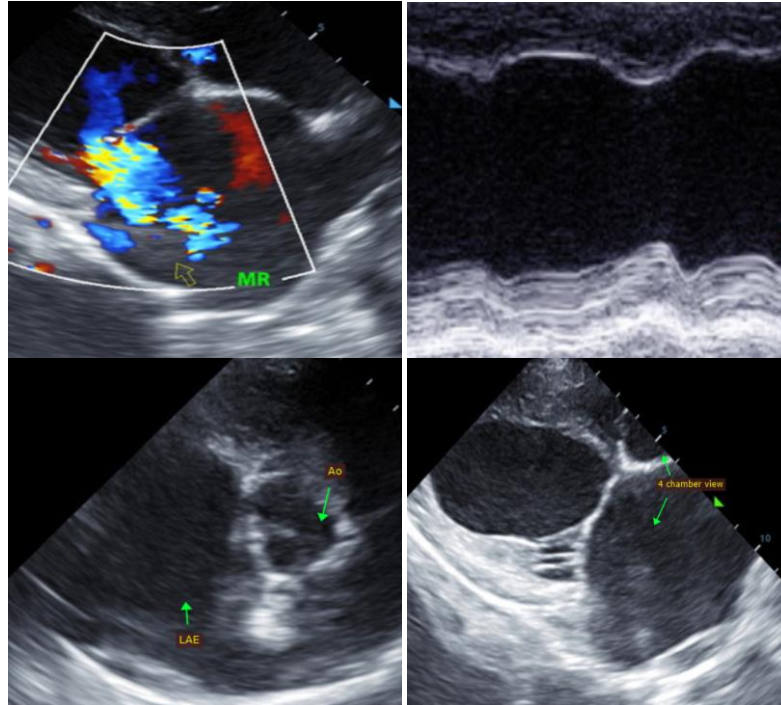
AGE

12 years

WEIGHT

78.7lbs

IMAGES



INTERPRETED BY

Maggie Machen Lamy,
DVM, DACVIM
(Cardiology)

IMAGING PERFORMED BY

Alastair Westcott,
DVM

HOSPITAL NAME

Alastair Westcott,
DVM

REFERRING VET

Dr. Westcott

INVOICE

27073

DATE

10/24/22

The information and recommendations provided are based on the images presented by the referring veterinarian. No evaluation can be communicated regarding pathology that was not visible in the image/video clips provided.

Thank you for this referral. This report was generated using transcription software, and minor dictation errors may be present. If the clinical or image interpretation does not parallel your findings or if I can be of any further assistance, please contact me.

Maggie Machen Lamy, DVM
Diplomate of the American College of Veterinary Internal Medicine (Cardiology)
info@sonopath.com